

# INNOVATIVE TECHNIQUES

## AESTHETIC RESTORATION OF ACQUIRED NASAL DEFECTS

ROBERT A. GUIDA, MD, BRYAN RUBACH, MD

Aesthetic restoration of acquired nasal defects has intrigued reconstructive surgeons for centuries. Because of the myriad reconstructive options, there is a need for a logical and sequential approach to the decision-making process used in choosing the appropriate reconstruction for a specific nasal defect. Based on a literature review and extensive clinical experience, a recommended outline is presented that is organized by location and size of the nasal defect.

Historically, 3 basic techniques evolved over the years for major nasal reconstruction. The Indian rhinoplasty, described as early as 2000 BC, used a pedicled forehead flap for nasal reconstruction. In the 15th century, medical literature in Italy detailed the brachial or arm flap for nasal reconstruction. In the 19th century, the French began reporting their work on the cheek flap for reconstruction of the nose.<sup>1,2</sup> Today, advances in local and regional flap reconstruction, tissue expansion, and improved methods of providing lining and support to the nose allow for excellent functional and cosmetic results, without regard to the size of the defect.

### ANATOMIC HIGHLIGHTS

The nose has been described as a separate aesthetic facial unit, consisting of concave and convex surfaces that demarcate distinct nasal subunits (Fig 1).<sup>3</sup> The tip is determined by the contour of the underlying lower lateral cartilages (LLC). Each side of the tip has an elevation or dome that drops off and blends in with the ala laterally and the nasal sidewall superiorly. A supratip depression marks the border of the tip and the dorsum. The dorsum extends from the supratip depression to the glabella. The lateral border of the dorsum forms a ridge that separates it from the nasal sidewall subunit. The lateral nasal sidewall extends from the lateral edge of the dorsum to form the nasofacial groove. The alar subunit (lobule) consists of a C-shaped alar groove that is shallow medially and deep laterally. There is no cartilaginous support to the alar subunit, unlike the tip, which is supported by the LLC. Finally, the soft triangle (facet) is a shallow depression between the arched caudal border of alar cartilage and nostril margin and is considered by

most rhinoplasty surgeons to be aesthetically pleasing and well worth preserving in nasal reconstructive surgery.

### REGIONAL SUBUNIT APPROACH

When reconstructing a nasal defect, it is helpful to visualize the various subunits in relation to the defect and attempt to preserve the integrity of their respective surfaces and boundaries. Incisions should be made so that scars approximate the natural contours of the nose. The surgeon can select for texture, thickness, and color of donor material, as well as location, length, shape, and direction of incisions and excisions.

The simplest repair often provides the best functional and cosmetic result. When simpler reconstructive methods result in excessive tension of skin edges or distortion of surrounding structures, a skin flap or graft must be considered. Specific flaps are more useful in certain situations. However, it is imperative to understand tissue movement and individualize each and every surgical defect before committing to one particular closure option. Each patient should be approached with a mental exercise in which all available reconstructive options are assessed. If a defect is particularly large with multiple areas of loose adjacent tissue, it may be closed with a combination of flaps, or a combination of a flap and a skin graft.

To achieve the best aesthetic result, scars created must be placed between the regional subunits. Flaps are designed to replace regional subunits rather than surgical defects. When a large part of a nasal subunit (greater than 50%) has been lost, one should replace the entire subunit rather than merely patching the defect. Whenever possible, camouflage scars within a wrinkle line or along borders of subunits.

### RECONSTRUCTIVE OPTIONS

There are numerous options for the varied and often complex nasal deformities that result from the excision of nasal cutaneous malignancies or from traumatic injuries. In reviewing the literature one will find that nearly every possible, and even im-

From the Division of Facial Plastic and Reconstructive Surgery, Department of Otolaryngology Head and Neck Surgery, Weill Medical College of Cornell University, New York, NY and the Center for Cosmetic and Laser Surgery, Aurora, IL.

Please address reprint requests to Robert A. Guida, MD, Facial Plastic and Reconstructive Surgery, 8 E 75th St, New York, NY 10021.

Copyright © 2000 by W.B. Saunders Company

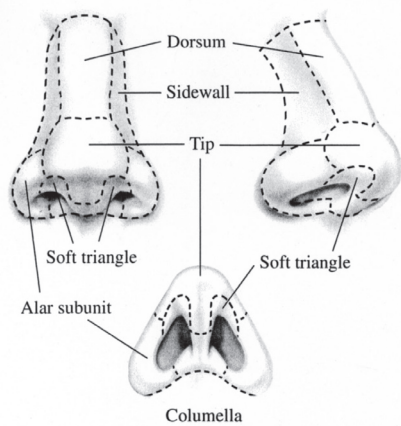


FIGURE 1. Nasal subunits

possible, technique has been attempted.<sup>4,5</sup> This article presents a general guide or outline

## NASAL RECONSTRUCTION OF THE LOWER ONE THIRD OF THE NOSE

Anatomy of the lower one third of the nose is distinctly different from the proximal two thirds. The skin here has limited mobility and therefore cannot be recruited for closure for anything but small defects. The color and sebaceous texture are unique so that neither distant nor local flaps provide good match. Finally, the free margins of the alar rims are mobile and easily distorted by imprecise closures. Reconstruction here is most challenging, and preoperative planning must be precise.

### TIP RECONSTRUCTION

#### Secondary Intention

Although allowing a nasal defect to heal by secondary intention is a rarely used option, it is mentioned first because it is certainly the simplest alternative and should be considered in smaller defects of the nasal tip.<sup>6</sup> This is especially true in lesions that are concave, partial thickness, and less than 1 cm in size. However, healing by secondary intention for larger tip defects may result in distortion of alar rims.

Secondary intention may also be considered as an option for debilitated or anticoagulated patients, so as not to expose them to the potential risk of prolonged anesthesia or a lengthy surgical procedure. With deeper defects on the tip, one may consider letting the wound granulate for 7 to 10 days, followed by a full-thickness skin graft (FTSG) to avoid a permanent concavity.

#### Local Flaps

**Bilobe Flap.** The bilobe flap is an excellent flap for closure of defects less than 1.5 cm on the lower one third of the nose, especially around the tip. It is a double transposition flap and is useful when the primary defect is located in inelastic skin and the adjacent skin is relatively mobile. Elastic skin, by means

of the double transposition, can indirectly be used to close the inelastic skin of the primary defect. For the nasal tip, the double transposition flap can borrow skin from the loose nasal dorsum or glabella to close the defect in the tight nasal tip.

Modification of the standard design can improve the results on the nose.<sup>7</sup> The standard design places the donor flap for the secondary defect 180° from the primary defect, with the donor flap for the original defect and the donor flap for the secondary defect having to each be rotated 90°. This results in a significant standing cone deformity at the point of rotation and maximizes tension on the overall flap. An improved design minimizes this problem. It involves transposing each flap only 45° degrees (a total of 90° to 100°), and a Burrow's triangle is included in the initial design of the flap. Wide undermining is necessary for the final closure.

The advantages of the flap are that it is single-staged and provides excellent color and texture match with little distortion. The results cosmetically are much better than those usually obtained with a skin graft. The disadvantages are that the bilobe flap involves numerous curved geometric lines crossing regional subunits, sometimes resulting in a "busy" scar. In addition, this flap is relatively complicated for the novice surgeon.

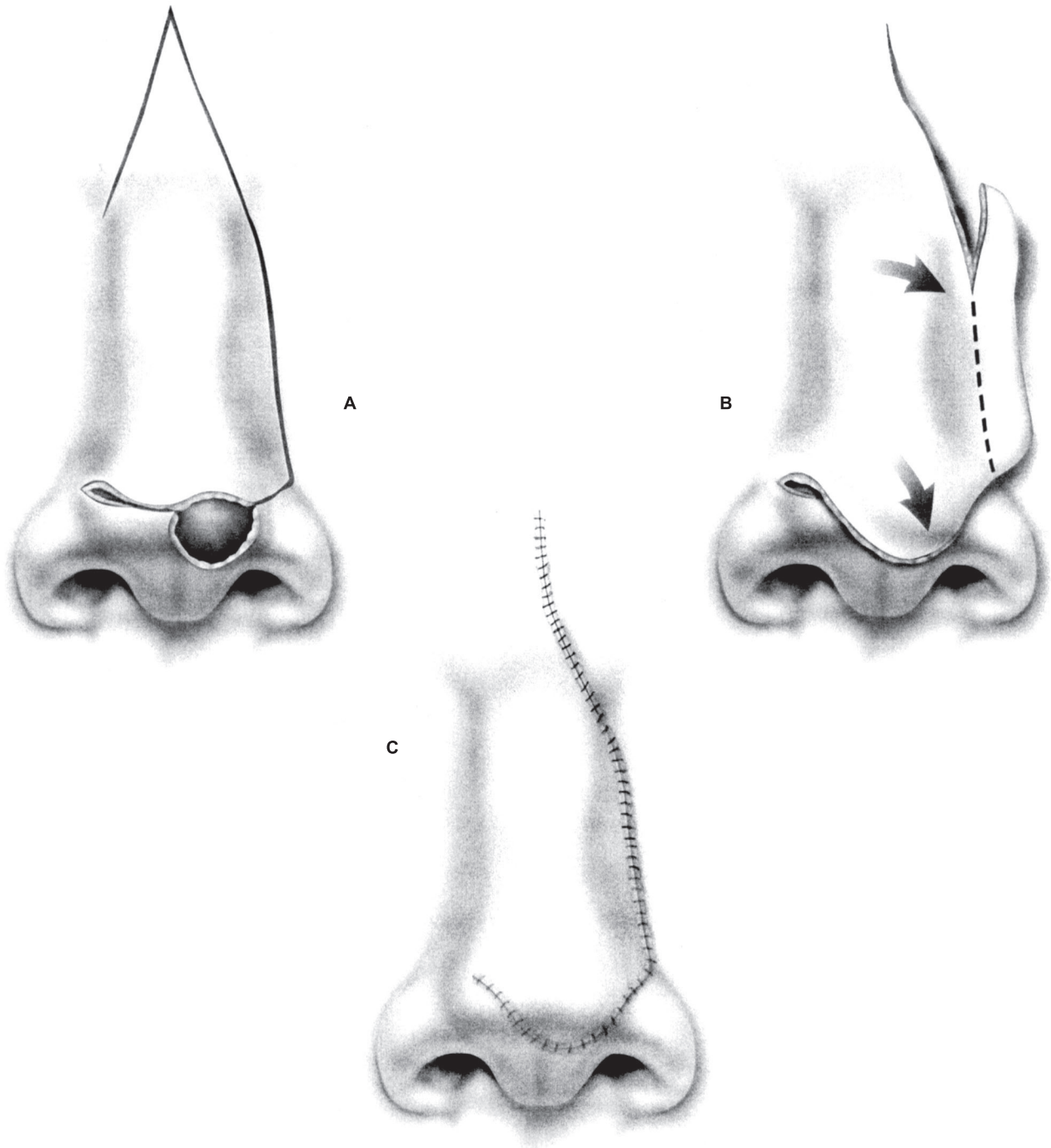
TABLE 1. Outline for Nasal Reconstruction

Lower $\frac{1}{3}$ of nose
Tip
Secondary intention (<1 cm)
Local flaps
Bilobe
Reiger (dorsal nasal flap)
Nasolabial
FTSG
STSG
Axial-pattern flaps
MFF
Nasal ala
Intact nostril margin
Nasolabial flap
Bilobe flap
Absent nostril margin
<1-cm composite graft
>1-cm nasolabial flap or MFF
Upper $\frac{2}{3}$ of nose
Primary closure
Rhombic transposition flap
Webster 30° flap
Cheek advancement flap
Reiger (dorsal nasal) flap
MFF
FTSG
Total nose
Coverage: MFF with or without other flap
Support:
Septal or auricular cartilage
Calvarial bone
Irradiated rib
Alloplastic material (Medpor [Porex Surgical Inc, College Park, GA], Alloderm [Lifecell Corp, Branchburg, NJ], Gore-Tex [W.L. Gore & Associates, Inc, Newark, DE])
Lining:
FTSG
Turn-down flaps
Septal mucosal flaps

Abbreviations: FTSG, full-thickness skin graft; STSG, split-thickness skin graft; MFF, midline forehead flap.

**Reiger or Dorsal Nasal Flap.** The Reiger flap offers excellent 1-staged closure for medium to large (1- to 3-cm) full-thickness defects of the distal and middle third of the nose.<sup>8</sup> It is a laterally based rotation-advancement flap, considered to be

both a random flap as well as an axial flap that is based on a branch of the angular artery, joining with the supraorbital arteries. The pedicle is located lateral and superior to the defect. A curvilinear line is drawn from the defect laterally in the



**FIGURE 2.** Steps for a Reiger flap. (A) A curvilinear line is drawn from the defect laterally, along the nasofacial sulcus, medial to the medial canthus, and into the superior aspect of the glabella. The height of the superior glabella extension of the incision should be 1.5 to 2 times the vertical height of the defect, with the backcut made toward the contralateral medial canthus. (B) The flap is rotated inferiorly, trimmed appropriately, and closed in a layered fashion. A standing cone deformity extending laterally from the defect should be removed at this time. (C) The flap is closed under minimal tension. Often, an M-plasty is needed to correct the standing cone lateral to the defect.

nasofacial sulcus, medial to the medial canthus and into the superior aspect of the glabella. The distance from the inferior glabella to the superior portion of glabellar portion of flap should be 1.5 to 2 times the vertical height of the nasal defect. A backcut is made to the contralateral medial canthus at a 30° to 45° angle. A wide undermining in the bloodless plane just superficial to the cartilaginous and bony nasal skeleton facilitates closure. The glabellar defect is closed in a V-Y fashion (Fig 2).

**Nasolabial Flap.** The nasolabial flap is a single transposition flap. It is not particularly useful for midline or nasal tip defects because of the length needed to reach these areas. It is best suited for lateral side wall, ala, and alar rim defects and will be discussed later.

### Full-Thickness Skin Graft

FTSG is composed of full-thickness epidermis and dermis. It can be very useful for most nasal tip defects, with minimal compromise of proper matching of color, texture, and consistency with adjacent nasal skin. Secondary spot carbon dioxide laser resurfacing 10 weeks to .3 months later may improve the cosmesis of the graft.

The preauricular FTSG is generally the graft of choice for tip defects because of its thickness and color match from sun exposure. The donor site is well camouflaged in the preauricular crease. For larger or rounded defects, the donor site can be closed with a rhombic transposition flap. One must be careful not to harvest hair-bearing skin, especially in males with a heavy beard.

### Split-Thickness Skin Graft

Split-thickness skin grafting (STSG) involves a transfer of epidermis and a portion of dermis. The advantages are that it provides good coverage with a high survival rate. It is best used for coverage after removal of very high-risk malignancies and acts as a window to monitor possible tumor recurrence. The disadvantage is that the STSG offers poor color and texture match and is rarely used for tip reconstruction.

### Axial Pattern Flaps: The Midline Forehead Flap

The unipedicled midline forehead flap (MFF) is an extremely reliable form of reconstruction for a variety of nasal deformities. It is an axial pattern flap based on I set of supratrochlear vessels and the dorsal nasal vessels.<sup>9</sup> The MFF works especially well for larger (greater than 1.5-cm) nasal tip defects providing abundant, well-vascularized tissue that can be transferred in a nondelayed fashion. Because of its anatomic proximity to the nose, forehead skin provides superb color and texture match. The thickness can be tailored to cover virtually any nasal defect, from total nasal loss to full-thickness defects of the lower one third of the nose, including the entire tip and columella. Furthermore, the donor site can almost always be closed primarily with minimal deformity.

The flap is designed in a unipedicled fashion with a strong effort to preserve the supratrochlear vessels. The nasal defect

is measured and a template is designed and placed at the superior aspect of the forehead flap adjacent to the hairline. Two parallel incisions of 1 cm in width are made extending from the hairline inferiorly to the unilateral vascular pedicle. The base of the pedicle is positioned between the median aspect of the brow and the medial canthus, thereby giving the flap greater length than that achieved with a bipedicled flap. The flap base is always designed contralateral to the side of the defect so that the arc of rotation from flap origin to inset is less than 180°, minimizing tension of the vascular pedicle. For most reconstructions, the distal two thirds of the flap can be elevated in the subcutaneous plane (Fig 3A and 3B). The flap length usually attained is approximately 6 to 9 cm. To gain additional length, surgeons have extended the flap obliquely away from the midline on 1 side of the hairline, whereas others have extended the incision into the hair bearing scalp. In recent years, both conventional and intraoperative tissue expansion has been used to increase flap length.

Once the flap and pedicle are fully mobilized, it is rotated approximately 180° and tailored to fit the nasal defect. Often especially for tip reconstruction, it is necessary to thin the flap aggressively while preserving the subdermal plexus. This prevents the need for revision debulking procedures. The donor site is closed by simply advancing the 2 lateral forehead flaps medially with closure in the midline. Donor site defects less than 3 cm often can be closed primarily. Vertical galeotomies and tissue expansion are helpful for closure in larger defects.

The pedicle is divided in 3 weeks unless the host bed is compromised in some way. Further thinning of the flap should be done at this time, if indicated. The remaining unused flap is trimmed and returned to the caudal aspect of the forehead (Fig 4, Fig 5).

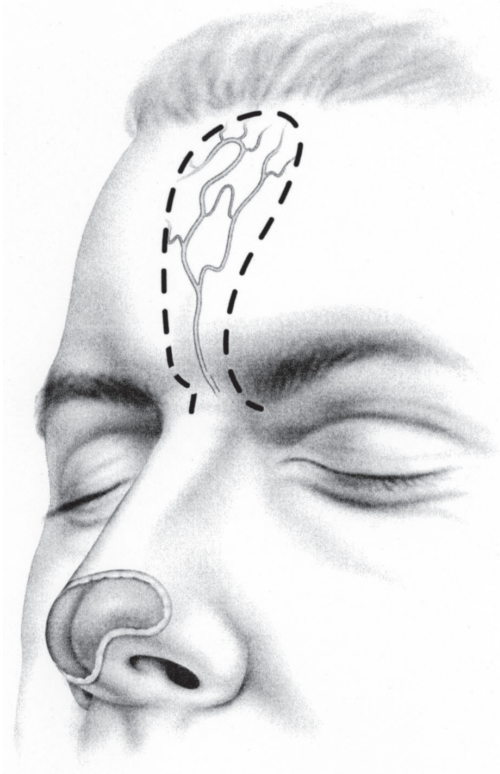


FIGURE 3. Design of unipedicle MFF.

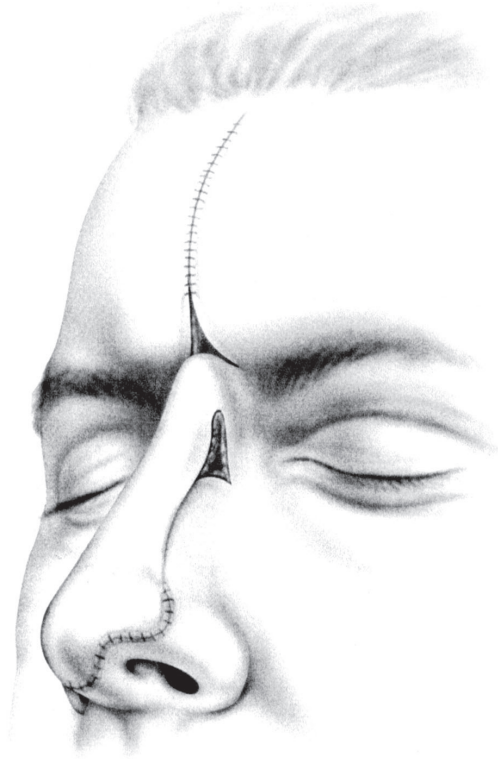


FIGURE 4. Release of pedicle of MIFF.

## NASAL ALA RECONSTRUCTION

### Intact Nostril Margin

**Nasolabial Flap.** The nasolabial flap is commonly used to repair defects of up to 2.5 cm on the lateral sidewall, ala, and alar rim defects. It is a random pattern transposition flap with the donor site on the cheek, adjacent to the melolabial fold. Abundant tissue is available in this area, and the skin has a very hearty blood supply. The flap can be based either superiorly or inferiorly. The donor site closure is easily hidden within the melolabial fold.

The traditional design of the nasolabial flap resulted in several cosmetically undesirable effects and therefore was underused by many surgeons. These drawbacks included pin cushioning or trapdoor defects, excessive fullness at the nasofacial groove obliterating this natural concavity, and the frequent need for 1 or more revisions. Several modifications proposed by Zitelli<sup>10</sup> allow for a reliable 1-stage reconstruction with no trapdoor deformity or the need for revisions. First, an excision of a Burrow's triangle at the superior edge of the defect toward the medial edge will eliminate the almost always present standing-cone deformity seen in the traditional design of the flap. Second, a periosteal suture from the dermis of the base of the flap to the maxillary periosteum helps to recreate the nasofacial sulcus. Third, wide undermining performed laterally but not medially aids in closure without distorting the alar rim. Finally, aggressive thinning of the distal flap prevents the need for future debulking procedures.

The flap can be folded onto itself for through and through

defects to recreate the alar margin. If it is used for larger defects or crosses the midline, it can be designed as a 2-staged pedicled flap. Inferiorly based flaps can be used for upper lip, floor of nose, and columellar defects.

The nasolabial flap does, however, have certain limitations. It should not be used for defects greater than 2.5 cm, limited by the laxity and inability to close the cheek donor site. For larger defects, a FTSG or a MFF provide better results. Also, defects on the nasal tip and midline dorsum require excessively long flaps, increasing the risk of a trapdoor deformity and distal flap necrosis.

**Bilobe Flap.** The bilobe flap works well for defects of less than 15 mm located on the lateral nasal tip and lower nasal sidewall. Flaps based medially are more appropriate for repair of alar defects, whereas laterally based flaps are most useful for defects near the tip. This flap, however, is much more useful for smaller lesions near the tip, as previously described.

### Absent Alar Margin Defects Less Than 1 cm

**Composite Grafts.** Both the nasal ala and the auricle are essentially cartilaginous frameworks covered by tightly adherent skin, making the auricle a logical choice for restoration of alar rim defects." Free composite grafts from the helical root are ideal for through and through alar defects. These grafts provide a single-staged closure with good color and texture match with nasal ala. The graft should be no more than 1.5 cm in size and should include only non-hair-bearing skin from the preauricular area. The donor site is easily closed by advancement superiorly of cheek skin (Fig 6).

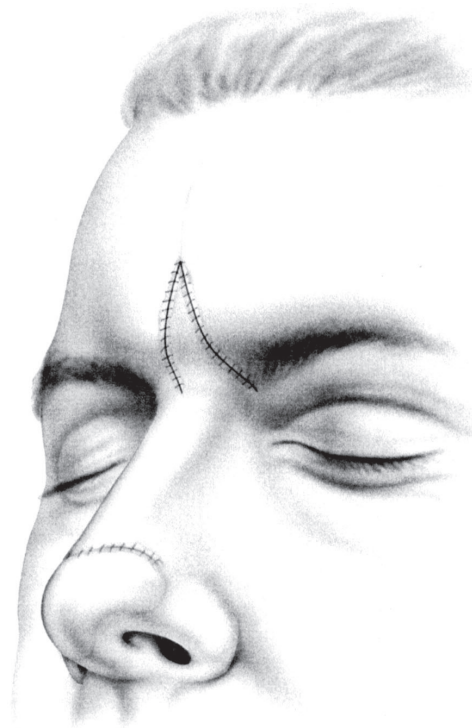

FIGURE 5. Pre-and postforehead flap

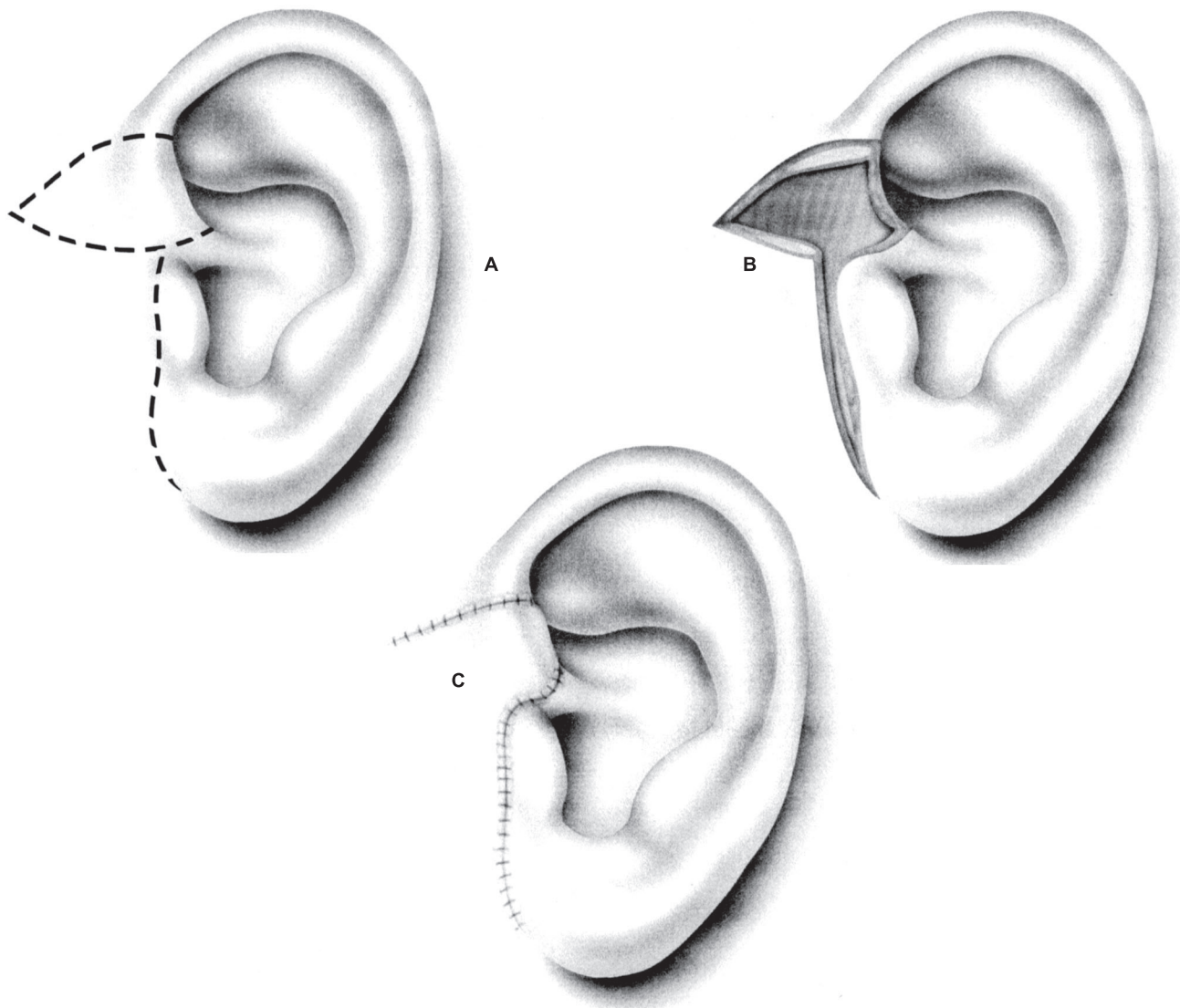
The limitations include variability and unpredictability of ultimate flap survival. It cannot be done in smokers or patients with small vessel disease such as diabetes or coronary artery disease, and the defect must be less than 1.5 cm in size.

To ensure success of the free composite graft, it must be less than 1.5 cm in its greatest dimension, be exposed to minimal intraoperative trauma, and be constantly kept moist intraoperatively. It is important to use no intraoperative vasoconstrictors and minimal electrocautery. A meticulous closure with 5-0 chromic suture for intranasal mucous membrane and 6-0 Prolene suture for skin, as well as postoperative cooling for 72 hours, helps ensure flap viability (Fig 7).

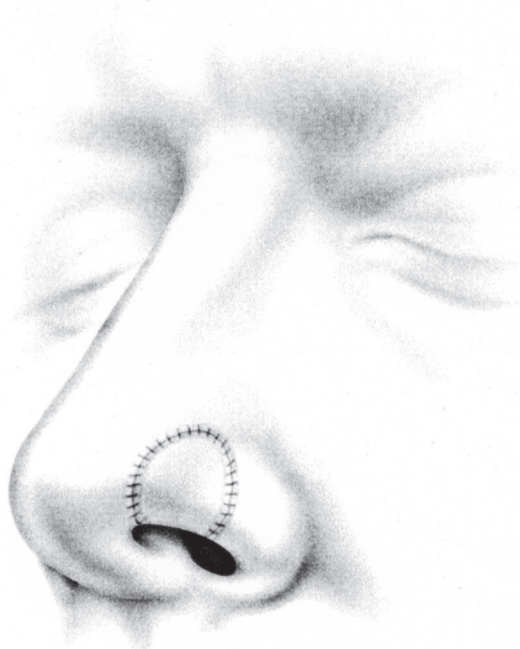**Nasolabial Flap.** As previously described, the nasolabial flap can be folded upon itself to provide lining as well as surface

coverage. The rich vascularity almost always ensures survival. However, the flap is almost always too thick, which not only causes an external bulge, but also narrows the nostril opening, compromising function.

**Midline Forehead Flap.** The MFF is the flap of choice for significant defects of the nasal ala and nasal tip, whether surface coverage only or both lining and coverage are needed. For full-thickness loss, lining can be provided by turn-down flaps of adjacent nasal skin, intranasal septal flaps, or FTSGs. The thickness of the distal end of the flap can be tailored to match the defect, and one should be very aggressive in thinning the distal end for tip defects. One should also remember to reconstruct the nose in total subunits and, if necessary, to excise normal skin to achieve this result.



**Figure 6.** Obtaining composite graft. (A) The donor site at the contralateral helical root is precisely marked out for through-and-through nasal alar defect, which should be no larger than 1.5 cm. The preauricular incision is necessary for advancement flap closure or the donor site effect. (B) The composite flap has been removed containing full thickness anterior skin, cartilage, and posterior skin. The inferior preauricular skin is undermined for closure. (C) Final closure with well-camouflaged incisions.



**FIGURE 7.** Patient status post composite graft.

## **NASAL RECONSTRUCTION OF THE UPPER TWO THIRDS OF THE NOSE**

### **PRIMARY CLOSURE**

Primary closure will often provide the best functional and cosmetic result. The skin of the upper two thirds is less sebaceous and somewhat more mobile than the lower two thirds, and there may be more opportunities to close smaller defects primarily. However, the laxity is limited and quite variable, often resulting in excessive wound tension and local distortion with primary closure in all but rather small defects.

Midline lesions on the upper two thirds of the nose should be closed in a vertical fashion when possible, with a minimum length to width ratio of 3:1. Wide undermining must be performed. Fusiform closures of the sidewall are usually obliquely oriented parallel to a line from the medial canthus to the supratip area. If upward retraction of the ala occurs, another closure option should be sought.

### **RHOMBIC FLAP**

The rhombic flap is traditionally one of the most useful flaps for repair of lesions of the upper two thirds of the nose. The short, straight lines help break up the scar, making it less perceptible than the curved lines of the rounded Banner flap. It is most suitable for defects from 1 to 2 cm, although this varies depending on laxity for closure of the donor defect.

Defects of the lower portion of the upper two thirds of the nose should have an inferiorly based flap to take advantage of the loose skin of the nasal sidewall. Skin of the upper sidewall near the medial canthus is not as lax and is therefore less useful for donor site.

The classic rhombic flap is constructed around a geometric 4-sided defect of equal side lengths and tip angles equal to 60° and 120°. The flap is drawn by bisecting the 120° angle with a

line the length of which is equal to the lines forming the initial parallelogram around the primary defect. The flap is then created by drawing another line from the free end parallel to one of the existing sides of the defect. The flap tip produced in this way equal 60°. Because the closure of the secondary defect creates the majority of the tension for the flap, orientation of the rhombic flap should be decided by examining the favorable relaxed skin tension lines with respect to closure of the defect. The rhombic flap is perhaps the most difficult flap to visualize geometrically, but once mastered, it is a workhorse flap for many reconstructive surgeons.

### **WEBSTER 30° FLAP**

The Webster 30° variation of the rhombic flap is very useful for small to medium-sized defects on the upper and middle third of the nose. The 30° flap is based on the principle of an ideal flap angle of 30° in which tension on the closure of both the primary and secondary defects can be shared over a greater area. Bilateral 30° Webster and bilateral rhombic flaps may be useful in midnasal defects. These flaps could result in considerable distortion of the nasal columella and alar rim when used for lower nasal defects in poorly selected patients.

### **CHEEK ADVANCEMENT FLAPS**

Cheek advancement flaps are helpful for lateral nasal defects involving the lateral nose and adjacent cheek. The incision is made in the subciliary line or within the nasofacial crease to the nasolabial fold. It is important to recreate the nasofacial junction, because blunting across this landmark can easily occur with this flap. This blunting is avoided by using a subperiosteal tacking suture. The suture is placed in the dermis of the advancing flap several millimeters behind the advancing tip of the flap to the periosteum of the underlying bone. This procedure will recreate the nasofacial junction and relieve tension on the flap tip. Cheek advancement flaps are often used in combination with other flaps such as the MFF for larger defects of the cheek and nose.

### **REIGER OR DORSAL NASAL FLAP**

The Reiger flap, discussed earlier in connection with tip reconstruction, provides a one-staged, aesthetically predictable closure for lesions ranging from 1 to 3 cm in diameter in the midportion of the upper two thirds of the nasal dorsum.

### **MIDLINE FOREHEAD FLAP**

The midline forehead flap is the flap of choice for defects too large to be repaired by local flaps. It is also useful for defects that would not do well with skin grafts, such as lesions with exposed bone, exposed cartilage, or tissue previously exposed to radiation therapy.

Full-thickness defects of the nasal dorsum require an outer covering, an inner lining, and a supporting framework. Inner lining can be provided by turn-down flaps of adjacent nasal tissue, by FTSG, or by mucosal flaps developed from inside

the nose. Skeletal support should be established before the resurfacing of the external nose. This can be achieved by using outer-table calvarial bone graft, autogenous or irradiated rib grafts, or synthetic material such as Medpor (Portex Surgical, Inc, College Park, GA)(porous polytetraethylene). Additional support for the tip can be provided with autogenous auricular or septal grafts.

## SUMMARY

Reconstruction of acquired nasal defects requires a thorough analysis of the deformity and a complete assessment of repair options. Care must be taken to respect the borders of the nasal subunits and carefully camouflage the incisions within the borders of these subunits. Additionally, proper selection of the appropriate repair to match color, texture, and thickness of the surrounding skin of the defect will ensure a cosmetically pleasing result.

## REFERENCES

1. Mazzola R, Marcus S: History of total nasal reconstruction with particular emphasis on the folded forehead flap technique. *Plast Reconstr Surg* 72:408-414,1983
2. McDowell F, Valone J, Brown J: Bibliography and historical note on plastic surgery of the nose. *Plast Reconstr Surg* 10:149-185, 1952
3. Burget G, Menick F: The subunit principle in nasal reconstruction. *Plast Reconstr Surg* 76:239-247,1985
4. Manson P, Iloopes J, Chambers R, et al: Algorithm for nasal reconstruction. *Am J Surg* 138:528-532, 1979
5. Barton F: Aesthetic aspects of partial nasal reconstruction. *Clin Plast Surg* 8:177-191, 1981
6. Zitelli J, Fazio M: Reconstruction of the nose with local flaps. *J Dermatol Surg Oncol* 17:184-189,1991
7. Zitelli J: The bilobed flap for nasal reconstruction. *Arch Dermatol* 125:957-959, 1989
8. Duric Y, Hilger PA, Waters K: A new flap for reliable nasal reconstruction. *J Otolaryngol* 27:327-331, 1982
9. Tardy M, Sykes J, Kron T: The precise midline forehead flap in reconstruction of the nose. *Clin Plast Surg* 12:481-494, 1985
10. Zitelli J: The nasolabial flap as a single-stage procedure. *Arch Dermatol* 126:1445-1448,1990
11. Maves M, Yessenow R: The use of composite auricular grafts in nasal reconstruction. *J Dermatol Surg Oncol* 14:994-999,1988